

DISCHARGE SUMMARY



Name	Rashmi Arora	Age	31	Sex	F	CR No.	828756	F.U.C.No.	603/05	Blood group	
Address	S-56 Uppals South Avenue, Shana Road Jangpura Hyderabad	D.O.A.	11/11/05	D.O.O.	17/11/05	D.O.D.	25/11/05	Wt.	70 Kg		

TO COME FOR FOLLOW-UP ON WEDNESDAY AT 2.00 P.M. IN SOPD ROOM -1

DIAGNOSIS $T_3 N_0 M_0$ Ca breast (R).

ADVICE → tab tamoxifen 20mg o.d. B.B.F → follow up in Surg 1
 → tab ceftun 500mg b.i.d. x 2 days FUC wed 2pm Room 1 on 30/11/05
 → to register in breast cancer clinic on Thursday Room 1 at 2pm. 1/12/05

HISTORY & PHYSICAL FINDINGS

lump (R) breast x 5 months noticed by patient; gradually red in size.
 O/E:- 5x5cm mass in (R) UOQ, smooth surface, B.C. breast & areola (N), hard in consistency, mobile, no axillary nodes in (R) axilla

OPERATIVE PROCEDURE (R) MRM + sentinel lymph node Bx + Level I+II+III ALND ANAESTHESIA ↓ GA

OPERATIVE FINDINGS
 - 6x5cm lump (R) UOQ
 - multiple enlarged hard axillary LN (+)
 - single blue node (+)

HOSPITAL COURSE

unremarkable, wound edge shows staining no e/o revision. Pt discharged - both axillary & pectoral drains & advised to empty at 8 am daily measure output & note syringe & to note output & to come for drain removal as soon as either drain 20ml or less output.

DISCHARGE SUMMARY



Name	Rashmi Arora	Age	31	Sex	F	CR No.	828756	F.U.C.No.	603/05	Blood group	
Address	S-156 Uppals South Road	D.O.A.	11/11/05	D.O.O.	17/11/05	D.O.D.	25/11/05	WT	70 Kg		

TO COME FOR FOLLOW-UP ON WEDNESDAY AT 2.00 P.M. IN SOPD ROOM -1

DIAGNOSIS T₃ N₀ M₀ Ca breast (R)

ADVICE → tab tamoxifen 20mg o.d. B.B.F → follow up in Surg 1
 → tab ceftriam 500mg b.i.d x 2 days FVC Wed 2pm Room 2 on 30/11/05
 → to register in breast cancer clinic on Thursday Room 1 at 2pm 1/12/05

HISTORY & PHYSICAL FINDINGS

lump (R) breast x 5 months noticed by patient; gradually red in size.
 O/E: 5x5cm mass in (R) V0Q, smooth surface, B.C. breast & axilla (N), hard in consistency, mobile, no lymph nodes in (R) axilla

OPERATIVE PROCEDURE (R) MRM + sentinel lymph node bx + level I+II+III Axilla ANAESTHESIA GA

OPERATIVE FINDINGS
 - 6x5cm lump (R) V0Q
 - multiple enlarged hard axillary LN (+)
 - single blue node (+)

HOSPITAL COURSE

unremarkable, wound edge shows staining no ep. necrosis. Pt discharged - both axillary & pectoral drains & advised to empty at 8 am daily measure output & use syringe & to note output & to come for drain removal as soon as either drain 20ml or less output.

INVESTIGATIONS

Date	Hb	TLC	ESR	Platelets	P.T.	Sugar	Urea	Na/K	Creatinine	ECG
12/11/05	13.2	6900		308,000		9.6	23	146/5.0	1.1	
17/1/05	10.3 postop Hb									

Date	Bil	Alk Phos	OT/PT	T. Pro/VAG	Amylase	Ca/P/UA	Others	Others
12/11/05	50.6	98	28/25	7.7/4.8/2.9				

Radiology	Date	Number
USG Breast		→ (R) breast large heterochronic in UOD, lobulated margins 27x26x25mm. c. calcification. Masses seen medial to the measuring 14 mm from 6 o'clock close satellite nodules.
USG Abdom	→ Adenoma	→ (L) Adrenal lesion (hypercholesterolemia)

HISTOPATHOLOGY	No.	Date
USG guided mass	05-30214	28/10/05 → compatible with metastatic Ca

MICROBIOLOGY

- PUS
- SPUTUM/BLOOD
- URINE

5/12/05
 (12) Drain Removal
 & Dressing
 Able

FOLLOW-UP
 01/11/05 Wound cleaning.
 One pectoral drain out.
 R. Tab Ceftum 1 tab. BD x 3 days
 • Tab Tamoxifen 20mg OD x to culture
 Hake

breast ointment

<i>[Signature]</i>
JUNIOR RESIDENT
<i>[Signature]</i>
SENIOR RESIDENT
<i>[Signature]</i>
CONSULTANT


Invalid without signatures of all.

OUTPATIENT BILL CUM RECEIPT
(DUPLICATE)

AHI ID : GN0000023658
 PATIENT NAME : Ms. Rashmi Arora
 SEX/AGE : FEMALE/34 Years
 CONSULTANT : Referral Doctor

BILL NO. : GNBOCH/09029436
 DATE : 11/08/2008 13:19
 REFERRED BY : DR ANITA

SL No	PARTICULARS	QTY.	RATE	TAX (Rs)	AMOUNT (Rs)
1	Nuclear Medicine				
1.1	PET CT Whole Body with Diagnosti c CT	1	21,000.00	0.00	21,000.00
Sub Total					21,000.00
2	Others				
2.1	Diagnos Service	1	0.00	0.00	0.00
Sub Total					0.00
Total					21,000.00
Add:Tax					0.00
Total Including Tax					21,000.00
LESS DISCOUNT					2,100.00
BILL AMOUNT					18,900.00
LESS: AMOUNT SETTLED					
(XXXXXXXXXXXX1002 GNRCCC/9004042 11/08/2008 [Credit Ca , Amex Card, Exp:09/2010) 18,900.00					18,900.00
TOTAL BALANCE DUE					0.00
BILL AMOUNT:Rs EIGHTEEN THOUSAND NINE HUNDRED ONLY					


 CASHIER
 (Jayant Mishra)

Give Early
date for the
patient

Dr. Reedy

CAC-36



ALL INDIA INSTITUTE OF MEDICAL SCIENCES
Department of Nuclear Medicine & PET
Ansari Nagar, New Delhi-110029
Tel: 91-11-26593210

(4)

Physician Request Form for Positron Emission Tomography (PET) Scan
(Please Note: Scan will not be done if form is not properly filled)

Name: Rashmi Singh Age: 31 Yrs. Sex: M F

Referred by: Dr. V. K. Jha Requisition Date: 10/11/11

CR No / OPD No. / Clinic: P2756

Brief Clinical History: Ch. Carcinoma Breast (M)

(M) MAM with
stomach and liver metastases
has with Metastasis (M) per hip

Treatment History:

Received RT

No other Medications

Please
excuse the
handwritten
signature

Past history: DM HT TB Renal failure Previous Malignancies

Investigations:

Bld Sugar: Fasting PP Random Date:

Ultrasound/ECHO/CT/MRI/Plain/Contrast:

Previous Nuclear Medicine/PET No. & Date

Indication of PET/CT: Initial Dx / Staging / Treatment Res. / Monitoring / Restaging / Prognostication

Desired Study: Whole Body PET (Eyes to thighs) Brain only Cardiac only

PTO



Date : 16/04/2008

Department of Radiation Oncology

Name : Miss. Rashmi Arora
Age : 33 yrs
Reg. No. : RT 08-1302
Diagnosis : Carcinoma Right Breast with Skeletal Metastases
Ref By : Dr. C. B. Koppiker

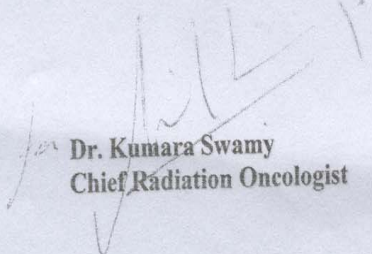
Treatment Given :

Patient received Palliative Radiation therapy to the bilateral pelvis using 15 MV photons to a dose of 2000 cGy in 5 fractions from 10/04/08 to 16/04/08.

Patient tolerated therapy well.

Advise :

To see Dr. C. B. Koppiker for further management.
To follow-up at Radiation Oncology OPD after 1 month and every three months subsequently for the next two years.


Dr. Kumara Swamy
Chief Radiation Oncologist

The only thing as relentless as cancer is our commitment to fight it !

40 Sassoon Road Pune - 411 001 Tel : 020 - 26123391 Fax : 020 - 26124529

BONE SCAN REPORT

PATIENT ID : 02705040801
NAME : Mrs. ARORA RASHMI
REF BY : Dr. Tapasvi Sachin

REPORT DATE :05/04/2008 12:34:20 PM
AGE : 33 Years SEX :Female

Indication: ca breast- operated 2 yrs ago, c/o left hip stiffness-2months- to rule out metastasis
Method: 20mCi of Tc99m Medronate was injected intravenously and whole body images were acquired at three hours.

Scan Findings:


Physiologic distribution of tracer is seen in the entire skeleton.

The left acetabulum, adjoining ischium and medial margin of ilium shows diffuse increased tracer uptake.

Both the kidneys are seen-normal finding.

Comments:

The left pelvic lesion needs further evaluation to rule out infective/ neoplastic pathology.



Dr. Sachin Tapasvi
Consultant


Dr. Shrikant Solav
M. D., DRM

MAIN CLINIC :
K - 2/1, Erandawana Co-op. Society,
Opp. Dinanath Mangeshkar Hospital,
Near Mahandale Garage, Pune - 411 004, (India)
Phones : (020) 25441125 / 25443576 / 25442557

BRANCH :
SPECT LAB
KEM Hospital,
4th Floor, TDH Building,
409 Rasta Peeth, Pune - 411 011.

आयकर विभाग
INCOME TAX DEPARTMENT



भारत सरकार
GOVT. OF INDIA

RASHMI ARORA

HARBANS LAL ARORA

17/06/1974

POLICE/Income Account Number

ACRPA5518U