

The Chariman,  
Smt. Krishana Breast Cancer Care  
Charitable Trust  
Tagore Nagar  
Ludhiana



Sir,

With due respect I beg to state that I have been advised admission by Dr. Ashish

DMC & H, Department of IRCH AIIMS (Medical oncology)

I am poor person and not in a position to pay normal charges. I therefore, request you to kindly provide me financial help because I am unable to pay the hospital bill & medicine bills.

**My particulars for your consideration: -**

Name of Patient LALY S. PILLAI Adm No. ....

Age & Sex 36 yrs Female Occupation NURSE

Gross Monthly Income - Place of work unemployed at present

Address.....

Yours faithfully,

LSPillai  
Signature of Pt. / Attendant

**Remarks of the Consultant :-**

Provisional Diagnosis Cancer @ Breast

If Surgery required Ex. Major, Major, Medium, Minor

approx cost.....

If Chemotherapy required stay ..... Medicine...

approx cost. Rs 60,00/- per cycle

- by Epi lirin
- by S FU
- by Endoxan

~ 4 cycle = Rs 24,000/-  
approximately



The pt. has had surgery and needs the above for her chemotherapy 4 cycles. I have seen the patient at home and their socio economic position is not good and they deserve financial help from you.

Dr. Divya Pr Singh  
06/04/09 Global Cancer Care India

Ph: 9810923584

The Chariman,  
Smt. Krishana Breast Cancer Care  
Charitable Trust  
Tagore Nagar  
Ludhiana



Sir,

With due respect I beg to state that I have been advised admission by Dr. Ashish

DMC & H, Department of IRCH AIIMS (Medical oncology)

I am poor person and not in a position to pay normal charges. I therefore, request you to kindly provide me financial help because I am unable to pay the hospital bill & medicine bills.

**My particulars for your consideration: -**

Name of Patient LALY S. PILLAI Adm No. ....

Age & Sex 36 yrs Female Occupation NURSE

Gross Monthly Income - Place of work unemployed at present

Address.....

Yours faithfully,

A. Pillai  
Signature of Pt. Attendant

**Remarks of the Consultant :-**

Provisional Diagnosis Cancer @ Breast


If Surgery required Ex. Major, Major, Medium, Minor

If Chemotherapy required stay ..... Medicine...

- by Epithin
- by SFU
- by Endoxan

approx cost.....

approx cost Rs 6,000/- per cycle  
x 4 cycle = Rs 24,000/-  
approximately



The pt. has had surgery and needs the above for her chemotherapy x 4 cycles. I have seen the patient at home and their socio economic position is not good and they deserve financial help from you.

Ashish  
06/04/09 Dr. Divya Pat Singh  
Colonial Cancer Cancer India

Ph: 9810923584



डा. बी. आर. अम्बेडकर संस्थान रोटरी कैंसर अस्पताल  
Dr. B.R. Ambedkar Institute Rotary Cancer Hospital  
अ.भा.आ.सं. अस्पताल / A.I.I.M.S. HOSPITAL

OPR-6

बहिरंग रोगी विभाग / Out Patient Department

अस्पताल के अन्दर धूम्रपान मना है। / SMOKING PROHIBITED IN HOSPITAL PREMISES

IRCH No. 117846 / 09

एकक / Unit  
विभाग / Dept.

IRCH No. 117846 Clinic No. 55765

egn. No.

नाम / Name

Name LALY S. PILLAI F/37 Yrs

जन तिथि / Date of Birth

W/O SH. K.S. PILLAI DOB 11/5/1972

Address H.NO. 1170, SECTOR-31, LIG, H.B. COLONY  
GURGAON Haryana INDIA

Clinic / OPI RADIO THERAPY EVALUATION

निदान / Diagnosis

Phone No. 9810084282/991096505 Room 4

Reg. Date 21/2/2009

दिनांक / Date

उपचार / Treatment

21 FEB 2009

ht: 165 cm.  
wt: 49 kg  
DSM: 1.5

Adv:

- 7d Endoxan 750mg IV D1
- 7d Epirubicin 120mg IV D1
- 7d SRU 75mg IV D1

Adv:

- Room No: 3
- Dr. Ashish.
- 6 cycles of CEF followed by RT.
- ER, PR, HER status.

Amble

hb, Hb, Dh, Ptt  
LFT, RFT, serum etc

21/2/09 on Tuesday 9AM

21/02/09

Cy 11/09

- Pronecler
- 05 fentanyl 750y IV + MS 10ml
- 05 Fentanyl 100y IV + MS 10ml
- 05 SRU 200y IV + MS 10ml
- Pan fentanyl 0.005
- Pan Dexam 10.005
- Cup Procain 10.005
- Pan 0.005 100y

6 ml

12/3/09

RIS on 12/3/09 - MS, Dexam, Procain

Cy 12/09

RIS on 12/3/09 - 2x meta doc 500y 100y  
Rpt TUE, AMEC

19/3/09

Cy 19/09

RIS on 19/3/09

RIS on 9/04/09

for Cy 19/09 i. MS, Dexam, Procain  
MS, MS, Procain

# Kharbanda Maternity & Nursing Home

New Railway Road, GURGAON (HR.) ☎ : 4065445

DR. (MRS.) NISHU KHARBANDA  
 M.B.B.S., M.D. (Obst. Gynae)  
 Consultant Gynaecologist  
 Regd. No. HN 550

Timing : 9.00 A.M. to 1.00 P.M.  
 : 5.30 P.M. to 8.00 P.M.  
 Sunday : 10.00 A.M. to 12.00 Noon

Mamud 12y

Mrs Lali

Prone of  
~~Breast~~  
~~mass +~~

Dated 7/11/08

Blood R<sub>x</sub>  
 sugar < F  
 PP

T/O  
 mass

IMP-20/10/08

Itchy Piv  
 Bwngum

VDRL < w

U side

Vag +

HIV I & II < w

Cap Perizole

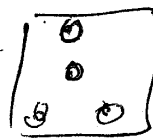
afk cont

1 box + 5

Mammography

CBUS4 Breast

Orflag kit



FNAC

mini (V) vag P<sub>1</sub>

1 HS x 6 d

Canded (B) out

Box

Ref to

Dr S. goel

for Breast  
 mass

Tag Lyser-D

1 box + 5 d



# M GOEL HOSPITAL

Ph. : 3291772

50-B & 77-C, Mianwali Colony, Gurgaon - 122001  
30 BEDDED MULTI-SPECIALITY HOSPITAL

**Dr. Sushil Goel**  
M.S.

Consultant Surgeon

**PHYSICIAN**

Dr. Harnesh Aggarwal, M.D.

**OBST. & GYNAECOLOGIST**

Dr. Anjali Dora, M.S.

Dr. Aika Goel, DNB

**CHILD SPECIALIST**

Dr. Naresh Garg, M.D.

**ORTHOPAEDIC SURGEON**

Dr. Rajesh Verma, M.S.

**LAPAROSCOPIC SURGEON**

Dr. Ashok Mittal, M.S.

**ENT**

Dr. Ravinder Gera, M.S., DNB

**UROLOGIST**

Dr. A. Khaitan, MCh

**NEUROSURGEON**

Dr. Rakesh Nathani, MCh

**ONCOSURGEON**

Dr. Dinesh Katiyar, MCh

**SKIN SPECIALIST**

Dr. V. Khara, M.D. (AIIMS)

11 a.m. - 1 p.m. (Sunday Closed)

**ANAESTHETISTS**

Dr. V.K. Kapoor, MD

Dr. L. Verma, MD

Dr. N. Dutt, DNB

Dr. V. Saluja, M.D.

**T.P.A. ON PANEL**

E-Meditek Solutions Ltd.

Alankit Health Care Ltd.

Vipul Med Corp. Pvt. Ltd.

Park Mediclaim Consultant Pvt. Ltd.

Safeway Mediclaim Services Pvt. Ltd.

East-West Assist.

T.T.K. Health Care Services Pvt. Ltd.

Medi Assist

Med Save Health Care Ltd.

MD India Services Pvt. Ltd.

Paramount Health Services P. Ltd.

Dedicated Health Services Pvt. Ltd.

Good Health Plan Ltd.

Focus Healthcare Pvt. Ltd.

Date : 18-11-2017

*hali*

*3CF*

*Lung B read (AT?)*

*upper & lower Esophagus*

*Mammoplasty } ? suspicious lesion  
4 Uls Breast*

*fovea - inconclusive*

*AE*

*INAC*

*my*

**Facilities :** ★ Multispeciality OPD ★ A/C & Non A/C Rooms ★ Economy Beds for Poor Patients ★ General Surgery ★ Urology ★ Orthopaedic Surgery ★ Plastic Surgery ★ Delivery, Caesarian Section ★ Vaccination ★ Well Equipped O.T. & Labour Room ★ X-Ray, E.C.G. & Lab ★ Laparoscopic Surgery ★ Paediatric Surgery ★ ENT Surgery ★ MTP & Infertility Clinic ★ Chemist Shop ★ Nursery for Neonates ★ Emergency 24 Hours

Charged Rs. 10/-

ओ भा० आ० सं० अस्पताल/A.I.I.M.S. HOSPITAL



बहिरंग रोगी विभाग / Out Patient Department

अस्पताल में अग्नि प्रयोग मना है। / SMOKING PROHIBITED IN HOSPITAL PREMISES

सोमवार प्रहल  
शुक्रवार पहला, तीसरा

OPR-6

S

एकक/Unit SURGERY

विभाग/Dept.

संज्ञांक/पंजीकृत सं०/O.P.D. Regn. No. 33194/2008

नाम/Name	पिता/पुत्र/पत्नी/पति/पुत्री F/S/W/H/D of W/O	लिंग Sex	आयु Age	पता/Address
LALLY S PILLAI	MR PILLAI	F	36 Y	1170 SEC-31 H B COLONY Haryana

निदान/Diagnosis

दिनांक/Date

5 DEC 2008

उपचार/Treatment

Room No. SURGERY. COUNTER  
5th Floor

family history of breast cancer

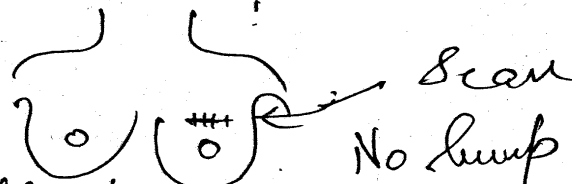
15/12/2008

out side operated → 6-12-08

Electronic  
Receipt OPD  
Stamp not  
needed

Histopathology  
MEDULLARY-CARCINOMA  
CA IS. 3CE A ER & PR

O/E-



No lump

Nipple/areola - Normal

Ⓟ Breast - Normal

Axilla, Neck - No nodes

Plan - Slide Review at AIIMS

अंगदान-जीवन का बहुमूल्य उपहार / ORGAN DONATION - A GIFT OF LIFE

O.R.B.O., AIIMS, 26588360, 26593444, www.orbo.org Helpline - 1060 (24 hrs service)

Pharmacy facility is available for outstation patients

MRI both breast

then - come to Wednesday 3pm

from ~~5~~ 1 for treatment plan


Dr. [unclear]

15-12-08

Core discussed in BCE

7/1/09

Single dx made 1x11m



Plan: WLE of Scar + treat AND STAB 1/11/09

MRI - only post of Scar

No other lesion noted

id Top  
for Admission

Please come on 19.07.09 for Admission

9868397227

07.01.09

help  
GBC/RT/KFT/Leur  
PRE in R. No. 5053



# All India Institute of Medical Sciences

Ansari Nagar, New Delhi-29

Department of Surgery, Unit I

## DISCHARGE SUMMARY

Name MRS LALLY PILLAI

Age/Sex 36 / F

DoA 19/01/200 CR No 52537

DoOp 1 21/01/200 Stay 10 days

Address 1170, SEC-31, HB COLONY GURGAON, HARYANA

DoD 29/01/200

Phone 9910964505 / 9810084282

Consultant Prof. Dr. Anurag Srivastav

Diagnosis LEFT CARCINOMA LEFT BREAST

Co Morbidity NONE

### Treatment on Discharge

1. Tab	CIPLOX 500 mg	1 tab	bd	x	5d
2. Tab	FLEXON	1 tab	tds	x	2d then sos
3. Tab	PANTOCID 40 mg	1 tab	bbf	x	15d 1/2 hr before breakfast

### Advice on Discharge

- Regular exercises and bathing.

To Follow up in Follow Up Clinic on Wednesday at 2:00 PM in room no 1, 5th floor, Surgery OPD

### History and Physical Findings on Admission

Mrs Lally Pillai presented in surgical OPD with complaints of previous lump one month old for which she was operated in private hospital on 6th dec 2008. no history of nipple discharge or retraction of nipple. No history of pain or metastatic symptoms.

Pulse: 78/min; BP: 120/80 mm Hg; Temp: 98°F; RR: 13/min. Wt: 48 Kg.

Conscious, Oriented. No Pallor, icterus or cyanosis. No generalized lymphadenopathy.

Abdomen : Soft, Non tender. No organomegaly or gross ascites. Bowel sounds present

Chest : B/L air entry present and equal. No ronchi or crepts audible.

CVS : S1, S2 normally heard. No click or murmur audible

CNS : Higher mental functions normal, All CN normal, No sensory/motor deficit.

### Procedure Performed

Left side Wle + Axillary Dissection done under General anesthesia.

### Intraoperative Findings

WLE OF SCAR WITH 2 CM MARGIN TILL PECTORAL FASCIA. LEVEL 1, 2, 3 DISSECTION DONE. ENLARGED LMPH NODES. NERVE TO SERRATUS ANTERIOR AND LATISSMUS DORSI PRESERVED.

### Hospital Course

Patient made uneventful recovery after surgery. No lethargy. No fevers. No malaise. Histopathology report awaited.

### Condition on Discharge

Vitals stable. Accepting feed orally and well tolerating. No fever. Wound healthy, no discharge. No Pain. Passing flatus. Passing Stools. Abdomen Soft. No tenderness. Chest: bilaterally clear. Blood pressure under control. Blood sugars under control.

9390086712  
Dr. Sahil

Blood Investigations											
Date	Hb	TLC	BLC (N/L/E/B/M)	ESR	PT (CP)	Platelet	BU	S. Cr	Na/K	Ca/PO <sub>4</sub>	Uric Acid
20/01/2009	13.3	3,700	-	-	-	312,000	17	0.9	149/5.5	9.3/2.8	3.8

Date	T. Bil	D/I	T. Prot	Alb/Glb	SGOT/PT	Alk Phos	Amylase	FBS	RES	PPS	T3	T4	TSH
20/01/2009	0.6	-	-	4.4/	22/17	-	-	-	113	-	-	-	-

Imaging				
S. No	Date	Type	Number	Report
1.	17/11/2008	USG BL BREASTS	PVT.	Birads 4.
2.	21/12/2008	MRI BREAST	PVT.	Underlying pectoral muscle normal. No enlarged lymph nodes. Mild thickening of left breast skin.
3.	07/01/2009	CHEST X RAY	PVT.	Normal study

Histopathology					
S. No.	Date	Type	Site	Number	Report
1.	29/12/2008	SLIDE REVIEW	LEFT BREAST LUMP	PVT.	Duct carcinoma
2.	18/11/2009	FNAC	LEFT BREAST LUMP	PVT.	Non-specific findings.
3.	06/12/2009	EXCISIONAL BX	LEFT BREAST LUMP	PVT.	Medullary ca of breast.

04/02/09

HPE Rpts awaited.

How healthy  
of him

① Tab version of using  
lab ID after meals

② Lab Pan 400 & 1000

Before breakfast every morning

Elastic Sleeve

Does wrinkle to  
Shoulder

To see with  
histology report

Anung Swastan  
4-2-09

To come to Room No: 4, ERCH, ground  
floor. Tuesday, Friday, Saturday

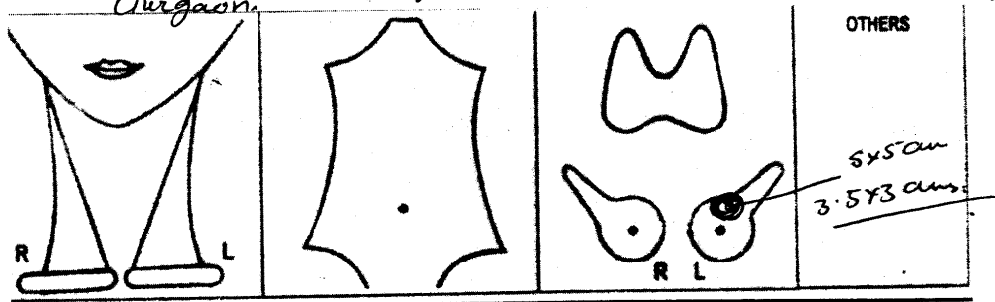
11/5/09  
Res. Little  
Consultant-In-Charge

Senior Resident

DR MAHESH  
(Resident-In-Charge)  
Page 2/2

Kindly fill up this form for Benign Breast Disease patient and return to Prof. Anurag Srivastava. Room 5035.  
**DATE SHEET FOR BENIGN BREAST DISEASE PATIENT**

Date of First Visit 15-12-08 Name: Lalys Pillai Age/sex 36/F Date of Birth 11-5-72  
 Phone 9810084282  
 Address: 1170 Sec-31 MB Colony (H)  
Surgaon.



Symptoms: Nipples Discharge - colour - duration: NO Single nipple/ Both nipple NO. family History :- Father. Brain Tumour

Pain: NO duration: site: Cyclical / noncyclical

Menstrual history: LMP: No. of children: Breast feeding-

Hormonal intake (estrogen / progesterone) duration dose

Subareolar sepsis: sinus or fistula - duration -site

Retraction of nipple: one - both congenital inversion-

Clinical features (show in diagram)

Out Side operability  
Histopathology-

**MEDULLARY-CARCINOMA**

Diagnosis clinical- CA 15.3 CEA ER/PR Pathological  
 Imaging findings-

Therapy- operations

Results- Cosmetic-

Recurrence of discharge-

Recurrence of Pain

Recurrence of sepsis